

Brief Communication

The mesoparasitic copepod *Pennella balaenopterae* and its significance as a visible indicator of health status in dolphins (*Delphinidae*): a review

Anna Vecchione¹ and Francisco Javier Aznar²

¹Research Director, Sea Life Conservation and Arts, Charleston, South Carolina, USA

²Unitat de Zoologia Marina, Institut Cavanilles de Biodiversitat i Biologia Evolutiva, Universitat de Valencia, PO Box 22085, Valencia 46071, Spain.

Abstract

Crustacean species of the genus *Pennella* (Copepoda, Siphonostomatoida, Pennellidae) are the largest mesoparasites known to infest cetaceans and marine bony fishes. *Pennella balaenopterae* is the species most commonly found semi-buried in the integument of members of dolphins (*Delphinidae*) and baleen whales (*Balaenopteridae*). This mesoparasite appears as a tag or filament hanging from the host's skin and is detectable even in free-ranging cetaceans. Under normal conditions, pennellid infestations are limited to only a few individuals per host. However, increased numbers of infestations by this epizootic crustacean have been reported recently. Here, the literature available on this parasite is reviewed. Since more numerical data are available for dolphins than the baleen whales, this paper focuses on the significance of *Pennella balaenopterae* infection in dolphins, and its possible value as an indicator of compromised health status. [JMATE. 2014;7(1):4-11]

Keywords: Parasite, Cetacean, Immune System, Infestation, Contaminant

Introduction

The mesoparasitic copepod *Pennella balaenopterae*, identified by Koren & Danielssen in 1877, has a broad biogeographic distribution. It has been found in the waters of Iceland, the Northeastern Atlantic Ocean, the Mediterranean Sea, the Antarctic, and the Northern Pacific (1, 5, 12, 15, 24, 29). The sei whale (*Balaenoptera borealis*) and the minke whale (*Balaenoptera acutorostrata*) are the most common final hosts of *P. balaenopterae*. Nonetheless, infestation can also occur in dolphins, such as the striped dolphin (*Stenella coeruleoalba*), and has been reported in the fin whale (*Balaenoptera physalus*) and rarely in pinnipeds (5, 12, 14). Thus the baleen whales and dolphins are the most common hosts reported to suffer these infestations.

Pennella balaenopterae (length, 8–32 cm) is the largest mesoparasite detected in the body tissue of cetaceans and is the only recorded copepod species that parasitizes marine mammals (1). Although the life cycle

of other copepods generally involves intermediate hosts, the intermediate host for *P. balaenopterae* and the number of moults required to reach the infective immature stage are unknown (21). Very little information is currently available on this parasite, particularly on its life history traits. It is known to survive in cold waters and significant information on its morphometry and anatomy has been published (1, 7, 24).

P. balaenopterae is a sexually dimorphic species and the female undergoes morphological changes at different stages of infestation. Only fertilized females parasitize cetaceans (5). Three main body parts (Figure 1) have been described: the cephalothorax, trunk, and abdomen (1). However, the morphological characteristics of the cephalothorax, apical papillae, and holdfast horns are inconsistent among this species and can even vary substantially between specimens of a single species (19). For example, the number of holdfast horns can be either 2 or 3, with higher numbers corresponding to greater embedding ability. This variation in horn number appears to be associated with the need for greater grip, based on observed differences in the levels of host penetration (1). Furthermore, differences in the lengths of the abdomen and trunk vary depending on the age of the parasite. Adult copepods have photoreceptors and antennae, or so-called cephalothoracic papillae, which have different shapes and outlines at the anterior end (19). The length and thickness of the first antenna were initially considered useful characteristics to distinguish between the two copepod species *P. balaenopterae* and *P. filosa*. However, recent studies have shown results obtained using these variables as a species indicator may be ambiguous (19). In the mature parasite, the function of the second antenna is not clear, although it may be of use during attachment in the infective stage of the



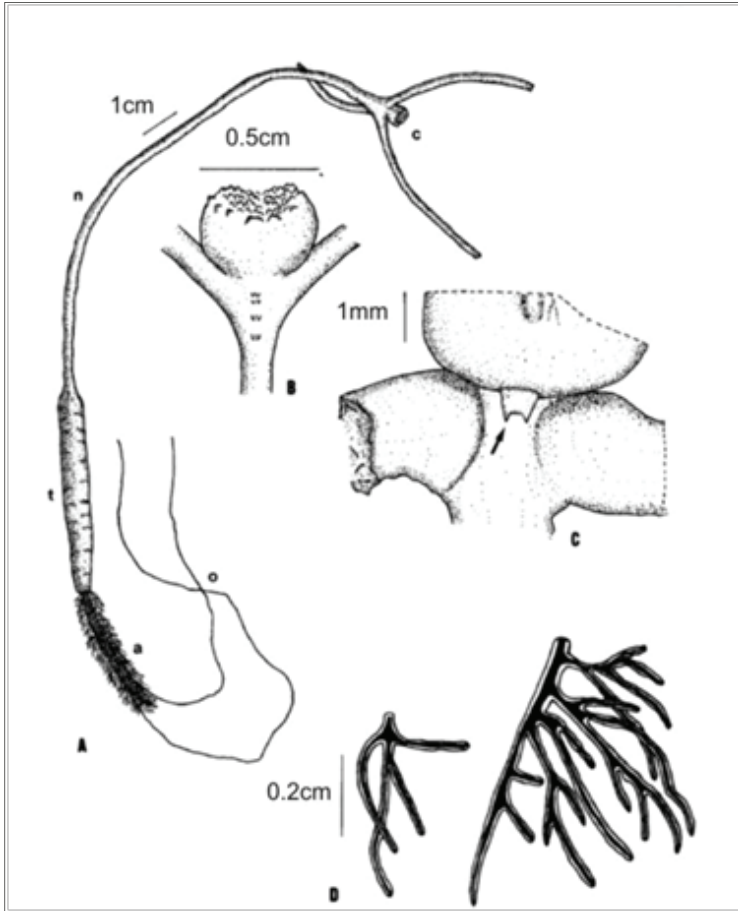


Figure 1: *Pennella balaenopterae*. A: general view of a specimen; B: ventral view of the cephalothorax and swimming legs; C: dorsal view of the cephalothorax showing cuticular structure (arrow); D: abdominal plumes with different level of branching (a: abdomen; c: cephalothorax; n: neck; o: ovisacs; t: trunk). Reproduced with permission.

copepod (1).

When the parasite first attaches to the host, it undergoes two phases of growth: growth of the anterior end and growth of the posterior end (used for reproduction). The posterior loose end of the gravid female has a visible, long, string-like ovisac (1). In *P. balaenopterae*, only the first naupliar stage (i.e. the free-swimming larval stage) and the adult female stages have been identified with certainty (24).

Although *P. balaenopterae* can infect dolphins and baleen whales, reports of infection in dolphins have increased in recent years and thus more data are available for them. Therefore, this review focuses on *Pennella* infections in dolphins and their possible utility as a general indicator of health status.

***P. balaenopterae* as a visual indicator of health status in cetaceans**

Monitoring the health of wild, free-ranging cetacean populations is challenging, particularly when live-capture options and laboratory resources are not available or are limited. In contrast, the recording of the numbers of skin parasites and their marks from a distance could be a useful and simple tool to obtain a rapid gross visual appraisal of health in free-ranging cetaceans if a correlation exists between numbers of visible parasites and overall health. Studies involving photographic assessments of skin disorders in cetaceans, such as common minke whales and white-beaked dolphins, have demonstrated that the dolphins can present clearly visible skin tattoos and keloidal lesions caused by poxviruses and lobomycosis (also known as lacaziosis) respectively (7, 10, 31).

Determining the biogeographic distribution of skin diseases can also be achieved with the use of photography, as revealed in studies conducted along the west- and east-central coasts of Florida. Photographic records of dolphins were utilized for health assessment in certain dolphin populations (10, 23, 31). *P. balaenopterae* infestation has the potential to also be valuable in helping researchers establish dolphin health status. Long-term, cumulative tendencies of *P. balaenopterae* infestation can be associated with a challenged dolphin's immune system. Under normal conditions, infestation is represented by only a few parasites (Figure 2). However, research has shown that a large number of epizootic crustacean infestations (Figure 3a, 3b) may be associated with debilitating viral infections (4, 5). One




Figure 2: Common minke whales with few parasites of *P. balaenopterae*, identified by red circles. Reproduced with permission Marie Louis/University of Iceland, Faxafloi Cetacean Research.

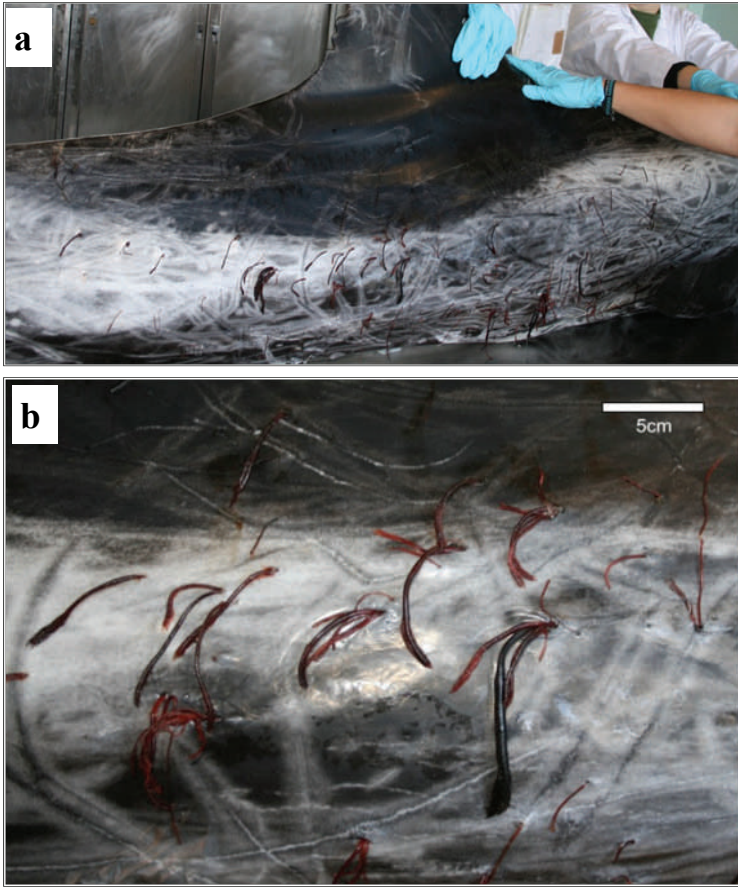


Figure 3: (a) View from lateral aspect of a heavily parasitized Risso's dolphin (*Grampus griseus*) from the Western Mediterranean; (b) Close-up of in situ individuals of *P. balaenopterae* from the heavily parasitized Risso's dolphin from the Western Mediterranean. Reproduced with permission from the Marine Zoology Unit, University of Valencia.

example is the high mortality reported in a cetacean morbillivirus outbreak in the 1990s in the western Mediterranean Sea. In the affected species, striped dolphin infestations of *P. balaenopterae*, and also those of the phoront cirriped *Xenobalanus globicipitis*, were commonly identified (4, 5). Data were obtained from records of striped dolphins stranded along the Mediterranean central coast of Spain from 1981 to 2004 (n = 136) (5). In these dolphins, prevalence, intensity of infestation, size and reproductive status of the commensal barnacle *Xenobalanus globicipitis* and *Pennella balaenopterae* were evaluated (Table 1). Results indicated that a significant increase of prevalence had occurred in the epizootic dolphin sample (n= 62), compared with the pre-epizootic (n = 12) and post-epizootic (n = 62) samples. A significant association between *X. globicipitis* and *P. balaenopterae* was also

observed, but only in the epizootic sample. Both patterns are compatible with the hypothesis that there was a short-term increase in the probability of infestation of these 2 species because of the sudden rise in the population of susceptible hosts (Table 1). The susceptibility was likely caused by the immunosuppressive effects of viral infection and the abnormally heavy loads of polychlorinated biphenyls which were detected in debilitated dolphins (5).

Other studies have demonstrated that most of the cetaceans found stranded on Italian coasts between 1990 and 1997 had skin lesions due to *P. balaenopterae* infestation (13, 32). This apparent increased vulnerability to *P. balaenopterae* infestation has been associated with the immunosuppressive effects of viral infections and the unusual heavy loads of pollutants found in debilitated dolphins. During the morbillivirus outbreak, substantial depletion of lymphoid tissue was a common finding in the analysed specimens (13). Several dolphin specimens also contained high levels of polychlorinated biphenyls, which are known to be a major contributing factor to immunosuppression (2, 5).

During post-mortem visual examination and surgical removal of the parasite, some characteristics and morphological variations of the holdfast horns of *P. balaenopterae* were representative of resistance encountered in the host. Specifically, the shape and length of holdfast horns can vary. When *P. balaenopterae* resides in a cetacean's soft blubber, its lateral horns are very long, whereas when it is found in the dense muscular layer below the blubber, its horns are relatively short (19). It is not clear whether there is a correlation between the host's immune reaction to the parasite and the length of its holdfast horns. However, successful infestation is an indication of the ability of *P. balaenopterae* to bypass the host's immune system, thereby embedding the anterior end completely into the host tissues. The parasite probably perforates the host's skin with the second antennae during the copepodid phase. Infestation progresses and anchorage of the anterior end is increased through the growth and grip of the holdfast horns. The cephalothorax of *P. balaenopterae* penetrates into the blubber, bypassing the host innate immune reaction and establishing an effective infestation. In some stranded cetaceans, granulomatous processes and secondary infections have been detected at the site of *P. balaenopterae* infestation.

Pre-epizootic (n= 12) (June-December 1981-1989)	Epizootic (n= 62) (June-December 1990)	Post-epizootic (n= 62) (June-December 1991-2004)
<i>Pennella balaenopterae</i>		
Prevalence=25.0 %	Prevalence=40.3 %	Prevalence=12.9 %
V/M=9.6	V/M=17.7	V/M=18.8
K could not be calculated	k=0.17	k=0.028
Median intensity=4	Median intensity=2	Median intensity=15
<i>Xenobalanus globicipitis</i>		
Prevalence=33.3 %	Prevalence=58.1 %	Prevalence=30.6%
V/M=31.7	V/M=22.0	V/M=72.3
k=0.109	k=0.27	k=0.073
Median intensity=6	Median intensity=6	Median intensity=10
n=number of dolphins in each sample, V/M=variance to mean ratio, k=parameter of negative binomial distribution (Aznar et al., 2005).		

Table 1. Infestation parameters of the mesoparasitic copepod *Pennella balaenopterae* and the phoront barnacle *Xenobalanus globicipitis* in striped dolphins (*Stenella coeruleoalba*) stranded along the Mediterranean coast of Spain in the period 1981-2004. Dolphins are divided into 3 groups, i.e. those that suffered a viral epizootic disease in 1990, and those stranded before and after this event. A significant change of prevalence of both species was observed during the epizootic event.

In particular, granulomatous or purulent inflammatory responses observed around chitinous remnants of the parasites are occasionally accompanied by opportunistic fungal and bacterial pathogens (22). During the development and growth of *P. balaenopterae*, the host immune system appears to allow for parasite survival. However, it remains to be established how the dolphin's immune system reacts to infestation and the parasite's fast growth rate. These factors may be important aspects that influence the outcome of the disease.

Detrimental changes in the immuno-physiological properties of marine mammals caused by environmental contaminants and the subsequent inefficient immune responses to pathogens have been demonstrated using

assays for molecular biomarkers and clinical chemical parameters as well as other laboratory-based methods (6, 18, 20, 34). Inefficient immune responses caused by substantial depletion of lymphoid tissue have been observed in striped dolphins, bottlenose dolphins (*Tursiops truncatus*) and Risso's dolphins (*Grampus griseus*) with *P. balaenopterae* infestation (13). Such lymphoid depletion might be related to reduced production of cytokines, which are important for both innate and adaptive immunity. Cytokines such as IL-1, IL-2, IL-4, IL-7, and IL-9 are responsible for the proliferation and differentiation of T-cells, B-cells, and macrophages, which are involved in acquired immunity. IL-3, granulocyte macrophage colony-stimulating factor,



and IL-5 are involved in the proliferation and differentiation of neutrophils, eosinophils, macrophages, and mast cells, which are implicated in innate immunity (33). As cetaceans share common characteristics in the structure, and possibly function, of cytokines with those of other mammals, cetacean exposure to pollutants probably has the same debilitating effect on cytokine production and function as observed in other mammalian species, consequently exerting a negative influence on the immune reaction to any pathogen (6, 32, 33). Severe *P. balaenopterae* infestation (Figure 3a, 3b) can lead to the death of dolphins due to malnourishment, toxicity caused by tissue necrosis or secondary infections at the site of parasite invasion (32). Morbillivirus-infected, pollutant-immunosuppressed, and heavily *Pennella*-infested dolphins predictably have a very small chance of survival, as evidenced by the dolphins stranded along the Mediterranean coasts between 1990 and 1991 (2, 5, 11, 13).

Worldwide anthropogenic contaminants are reaching threshold levels, leading to immunosuppression in marine mammals. In Atlantic bottlenose dolphins off the coast of Charleston, South Carolina, USA, chronic exposure to high levels of perfluoroalkyl compounds (PFCs) has caused changes in immunological parameters for both innate and adaptive immunity (17, 18). Visible skin diseases, such as lobomycosis, have been reported to be at epidemic proportions in Atlantic Ocean coastal waters, particularly among dolphins in the Indian River Lagoon of Florida. Localization of the disease to the southern portion of the lagoon indicated that exposure to environmental stressors could be responsible for the high prevalence of the disease (26). While there are no published reports of *P. balaenopterae* infestation in dolphins inhabiting the coastal waters of the Indian River Lagoon and Charleston, South Carolina, these populations of free-ranging dolphins are susceptible to morbillivirus infection like the dolphin populations of the Mediterranean Sea (3, 27). Further investigation of the presence of *P. balaenopterae* in Atlantic Ocean coastal waters is needed to understand the life cycle, ecology, and dynamics of this puzzling parasite, and its relation to pollutants and viral infections.

Lack of scientific data is most often attributed to absence of financial resources. However, in Charleston, South Carolina, several nature-based organizations provide coastal expeditions for tourists. Dolphin

encounters are a common occurrence during these expeditions. Some of these organizations are willing to volunteer and consequently collaborate with local scientists to report any sighting of *Pennella* on the dolphins they encounter. Data obtained by these collaborations with community-based organizations will help to establish the prevalence of *P. balaenopterae* in local dolphin populations.

In addition to the immunodeficiency caused by pollutants and morbillivirus, another possible suggested explanation for the increased *P. balaenopterae* infection rate is that sickness-induced lethargy may have impaired breaching or fast movements that would normally have shaken off the parasites (4). Abnormal lack of energy is frequently associated with illnesses. Consequently, behaviours that allow infestation of a large number of *P. balaenopterae* on the host are clearly an indicator of compromised health.

The presence of a visibly high number of skin parasites and diseases is a useful signal for a preliminary health appraisal of wild free-ranging dolphins. Monitoring the skin health of cetaceans using photographic identification is feasible, effective, and non-invasive, despite concerns associated with partial body exposure, which could impair complete skin evaluation (7). This concern is dependent on breaching behaviors, where, for some, full body assessments may be done if breaching is significant as shown in Figure 4. Visual surveillance of skin diseases during assessment of cetacean health is of particular relevance, considering



Figure 4: Risso's dolphin, *Grampus griseus* from the Western Mediterranean showing that even ventral surface parasites can be identified with breaching behaviors. Reproduced with permission.

the fact that marine mammals are representative sentinels of the health of oceans (8).

Conclusion

The presence of a large number of epizootic parasites or mesoparasites such as *P. balaenopterae* on dolphins is a possible indicator of biological or environmental changes in their ecosystem, which are affecting the dolphins' immune responses. The body structure and the typical dorsal or lateral location of *P. balaenopterae* are ideal for photographic identification. To the viewer, the parasite appears as a tag or filament hanging on the dolphin's skin. Under normal circumstances, infestation is limited to only a few individuals per host. However, an increased number of *P. balaenopterae* could serve as a marker for other more serious health issues such as an imbalanced immune system and secondary infections at the site of parasitosis, as shown by events documented during the 1990 dolphin morbillivirus outbreak in the Mediterranean Sea.

In conclusion, increased parasitosis of *P. balaenopterae* represents a significant visible indicator of dolphin health status. Consequently, the presence of this parasite should be monitored widely, notably in areas where dolphin populations have been exposed to toxic compounds and morbillivirus outbreaks, such as areas surrounding the Southeast US coast and, in particular, the coastal waters of South Carolina.

Acknowledgments

We wish to thank Dr Paulo Abaunza Martinez, Chiara Bertulli, Marie Louis, Igor Kiporuk for providing figures and photographs. Also, the first author is grateful to Concetta Dorio Tornincasa for her long-term support, Dr Giannina Convertino and Brian O'Neal for help in editing the manuscript, and Dr Koen Van Waerebeek for his friendship and constructive criticism. Project funding was provided by Sea Life Conservation and Arts; Project CGL2012-39545 from the Ministry of Economy and Competitiveness, Spain; and Project PROMETEO/2011/040 from the Generalitat Valenciana, Spain. There is no conflict of interest to declare.

References

1. Abaunza P, Arroyo NL, Preciado I. A contribution to the knowledge on the morphometry and the anatomical characters of *Pennella balaenopterae* (Copepoda, Siphonostomatoida, Pennellidae) with special reference to the buccal complex. *Crustaceana* 74:193-210. 2001.
2. Aguilar A, Borrell A. Abnormally high polychlorinated biphenyl levels in striped dolphins (*Stenella coeruleoalba*) affected by the 1990-1992 Mediterranean epizootic. *Science of the Total Environment* 154:237-247. 1994.
3. Aguilar A, Raga JA. The striped dolphin epizootic in the Mediterranean Sea. *Ambio* 22:524-528. 1993.
4. Aznar FJ, Balbuena JA, Raga JA. Are epizootes biological indicators of a western Mediterranean striped dolphin die-off? *Diseases of Aquatic Organisms* 18:159-163. 1994.
5. Aznar FJ, Perdiguero D, Pérez del Olmo A, Repullés A, Agustí C, Raga JA. Changes in epizootic crustacean infestations during cetacean die-offs: the mass mortality of Mediterranean striped dolphins *Stenella coeruleoalba* revisited. *Diseases of Aquatic Organisms* 67:239-247. 2005.
6. Beineke A, Siebert U, Wohlsein P, Baumgärtner W. Immunology of whales and dolphins. *Veterinary Immunology and Immunopathology* 133:81-94. 2010.
7. Bertulli CG, Cecchetti A, Van Bressemer MF, Van Waerebeek K. Skin disorders in common minke whales and white-beaked dolphins off Iceland, a photographic assessment. *Journal of Marine Animals and Their Ecology* 5:29-40. 2012.
8. Bossart GD. Marine mammals as sentinel species for oceans and human health. *Veterinary Pathology* 48:676-690. 2011.
9. Bossart GD, Romano TA, Peden-Adams MM, Schaefer A, McCulloch S, Goldstein JD, et al. Clinicoimmunopathologic findings in Atlantic bottlenose dolphins *Tursiops truncatus* with positive cetacean morbillivirus antibody titers. *Diseases of Aquatic Organisms* 97:103-112. 2011.
10. Burdett Hart L, Rotstein DS, Wells RS, Bassos-Hull K, Schwacke LH. Lacaziosis and lacaziosis-like prevalence among wild, common bottlenose dolphins *Tursiops truncatus* from the west coast of Florida, USA. *Diseases of Aquatic Organisms* 95:49-56. 2011.
11. Cerioni S, Mariniello L. Parasitic metazoans of *Stenella coeruleoalba* (Cetacea: Delphinidae) stranded along the coast of Latium, 1985-1991. *Parassitologia* 38:505-510 [In Italian]. 1996.

12. Çiçek E, Oktener A, Capar OB. First report of *Pennella balaenopterae* Koren and Danielssen, 1877 (Copepoda: Pennellidae) from Turkey. *Turkiye Parazitoloji Dergisi* 31:239-241. 2007.
13. Cornaglia E, Rebora L, Gili C, Di Guardo G. Histopathological and immunohistochemical studies on cetaceans found stranded on the coast of Italy between 1990 and 1997. *Journal of Veterinary Medicine A, Pathology, Clinical Medicine* 47:129-142. 2000.
14. Dailey MD, Haulena M, Lawrence J. First report of a parasitic copepod (*Pennella balaenopterae*) infestation in a pinniped. *Journal of Zoo and Wildlife Medicine* 33:62-65. 2002.
15. Dailey MD, Vogelbein W. Parasite fauna of three species of Antarctic whales with reference to their use as potential stock indicators. *Fishery Bulletin* 89:355-364. 1991.
16. Di Guardo G, Mazzariol S, Fernández A. Biologically threatened dolphins and whales. *Environmental Microbiology* 13:2833-2834. 2011.
17. Fair PA, Houde M, Hulsey TC, Bossart GD, Adams J, Balthis L, et al. Assessment of perfluorinated compounds (PFCs) in plasma of bottlenose dolphins from two Southeast US estuarine areas: relationship with age, sex and geographic locations. *Marine Pollution Bulletin* 64:66-74. 2012.
18. Fair PA, Romano T, Schaefer AM, Reif JS, Bossart GD, Houde M, et al. Associations between perfluoroalkyl compounds and immune and clinical chemistry parameters in highly exposed bottlenose dolphins (*Tursiops truncatus*). *Environmental Toxicology and Chemistry* 32:736-746. 2013.
19. Hogans WE. Morphological variation in *Pennella balaenopterae* and *P. filosa* (Copepoda: Pennellidae) with a review of the genus *Pennella* Oken, 1816 parasitic on Cetacea. *Bulletin of Marine Science* 40:442-453. 1987.
20. Hogue J, Keller JM, Reiner JL, Kucklick JR, Bryan CE, Moors AJ, et al. Spatial and temporal trends of persistent organic pollutants and mercury in beluga whales (*Delphinapterus leucas*) from Alaska. *Science of the Total Environment* 449:285-294. 2013.
21. Kabata Z. Volume 152: *Parasitic Copepoda of British fishes*. Ray Society Publications, pp. 1-468. 1979.
22. Mazzariol S, Di Guardo G, Petrella A, Marsili L, Fossi CM, Leonzio C, et al. Sometimes sperm whales (*Physeter macrocephalus*) cannot find their way back to the high seas: a multidisciplinary study on a mass stranding. *PLoS One* 6:e19417. 2011.
23. Murdoch ME, Mazzoil M, McCulloch S, Bechdel S, O'Corry-Crowe G, Bossart GD, et al. Lacaziosis in bottlenose dolphins *Tursiops truncatus* along the coastal Atlantic Ocean, Florida, USA. *Diseases of Aquatic Organisms* 92:69-73. 2010.
24. Olafsdóttir D, Shinn AP. Epibiotic macrofauna on common minke whales, *Balaenoptera acutorostrata* Lacépède, 1804, in Icelandic waters. *Parasites & Vectors* 6:105. 2013.
25. Reif JS, Mazzoil MS, McCulloch SD, Varela RA, Fair PA, Bossart GD. Lobomycosis in Atlantic bottlenose dolphins (*Tursiops truncatus*) from the Indian River Lagoon, Florida. *Journal of the American Veterinary Association* 22B:104-108. 2006.
26. Reif JS, Peden-Adams MM, Romano TA, Rice CD, Fair PA, Bossart GD. Immune dysfunction in Atlantic bottlenose dolphins (*Tursiops truncatus*) with lobomycosis. *Medical Mycology* 47:125-135. 2009.
27. Rowles TK, Schwacke LS, Wells RS, Saliki JT, Hansen L, Hohn A, et al. Evidence of susceptibility to morbillivirus infection in cetaceans from the United States. *Marine Mammal Science* 27:1-19. 2011.
28. Schaefer AM, Reif JS, Goldstein JD, Fair PA, Bossart GD. Serological evidence of exposure to viral and bacterial pathogens in free-ranging Atlantic bottlenose dolphins (*Tursiops truncatus*) from the Indian River Lagoon, Florida and Charleston, South Carolina. *Aquatic Mammals* 35:163-170. 2009.
29. Uchida A, Kawakami Y, Yuzu S, Kishikawa S, Kuramochi T. Prevalence of parasites and histopathology of parasitization in minke whales from the Western North Pacific Ocean and Southern Sea of Okhotsk. *Report of the*



- International Whaling Commission*, 48:475-479. 1998.
30. Valsecchi E, Amos W, Raga JA, Podestà M, Sherwin W. The effects of inbreeding on mortality during a morbillivirus outbreak in the Mediterranean striped dolphin (*Stenella coeruleoalba*). *Animal Conservation* 7:139-146. 2004.
 31. Van Bresse MF, Van Waerebeek K, Aznar FJ, Raga JA, Jepson PD, Duignan P, *et al.* Epidemiological pattern of tattoo skin disease: a potential general health indicator for cetaceans. *Diseases of Aquatic Organisms* 85:225-237. 2009.
 32. Vecchione A. *Pennella* parasite in *Stenella coeruleoalba*. Italian marine ecosystem of the coast of Latium. *Seminario Internazionale di Studi di Ecosistema Marino* 96-98. 1994.
 33. Vecchione A, Peden-Adams MM, Romano TA, Fair PA. Recent cytokine findings and implications towards health assessment of bottlenose dolphin (*Tursiops truncatus*). *Aquatic Mammals* 34:93-101. 2008.
 34. Weirup L, Müller S, Ronnenberg K, Rosenberger T, Siebert U, Lehnert K. Immune-relevant and new xenobiotic molecular biomarkers to assess anthropogenic stress in seals. *Marine Environmental Research* 92:43-51. 2013.